

Enhanced Axillary Evaluation Using Reflector-Guided Sentinel Lymph Node Biopsy: A Prospective Feasibility Study and Comparison With Conventional Lymphatic Mapping Techniques

Bret Taback,¹ Priya Jadeja,¹ Richard Ha²

Abstract

Breast cancer patients with nodal involvement often undergo neoadjuvant chemotherapy. The previously biopsied node (PBN) provides the most accurate information regarding treatment response. This study aimed to evaluate the success of a reflector-guided excision of the PBN to predict the response of the axilla. The reflector described in this report effectively targets the PBN without institutional safety concerns, and reflects the status of the axilla in all cases.

Background: Recently there are efforts to use sentinel lymph node biopsy (SLNB) techniques after neoadjuvant chemotherapy (NAC) to minimize axillary surgery. However, studies have shown higher false negative rates in this scenario, which might result in inaccurate assessment of treatment response and patient prognosis as well as leaving residual disease behind. In this study, we describe the use of reflector-guided excision of the percutaneously biopsied node (PBN) as an aid to conventional SLNB and its predictor of the axillary status after NAC. **Patients and Methods:** This was a single-institution analysis of patients who underwent axillary fiducial-reflector placement and subsequent SLNB compared with conventional SLNB. **Results:** Nineteen patients in the reflector group were matched with 19 patients who underwent conventional SLNB (conventional group). The PBN was identified in the SLNB in 19 patients (100%) in the reflector group and in 9 patients (47.3%) in the conventional group ($P = .002$). In the remaining 10 patients in the conventional group, the PBN was identified in the axillary lymph node dissection specimen in 4 patients (21%) and not identified in 6 patients (31.7%). Among the 38 patients, traditional mapping failed to identify the PBN in 13 patients (34.2%). The PBN was negative in 10 patients (36%) and positive in 18 patients (64%); no additional positive nodes were identified among patients with a negative PBN, correctly reflecting the status of the axilla in 100% of cases. **Conclusion:** Mapping failure after NAC might compromise SLNB. Reflector-guided excision of the PBN is not only facile and feasible, but more accurately reflects the status of the axilla after NAC.

Clinical Breast Cancer, Vol. ■, No. ■, ■-■ © 2018 Elsevier Inc. All rights reserved.

Keywords: Axillary dissection, Axillary response, Neoadjuvant chemotherapy, Novel techniques, Targeted lymph node dissection

¹Department of Breast Surgery

²Department of Breast Imaging, Columbia University Medical Center, New York, NY

Submitted: Jan 6, 2018; Revised: Feb 4, 2018; Accepted: Feb 5, 2018

Address for correspondence: Bret Taback, MD, Department of Breast Surgery, Columbia University Medical Center, 161 Fort Washington Ave, Herbert Irving Pavilion, 10th Floor, New York, NY 10032
E-mail contact: bt2160@cumc.columbia.edu

Introduction

Identification of axillary nodal metastasis at the time of breast cancer diagnosis guides multimodal treatment planning. Improvements in preoperative imaging and molecular subtyping allow tailored options for neoadjuvant chemotherapy (NAC). Recently, there have been concerted efforts to minimize axillary surgery in patients who respond to NAC.^{1,2}

Initial trials in sentinel lymph node (SLN) biopsy (SLNB) identified the false negative rate (FNR) as 7% to 10% in patients with early-stage breast cancer who underwent upfront surgical

Reflector-Guided Sentinel Lymph Node Biopsy

treatment.³⁻⁶ This evolved to single-center studies of patients who underwent SLNB after NAC with a FNR of 0 to 20%.⁷ More recent multicenter trials on the utility of SLNB after NAC showed a slightly higher FNR of SLN identification of between 11% and 15% with a meta-analysis showing an average of 14%.^{1,2,6,8,9} The largest study to date, the American College of Surgeons Oncology Group (ACOSOG) Z1071 trial, evaluated the role of SLNB after NAC in patients who presented with node-positive disease and identified a higher FNR of SLNB after NAC as 12.6%.¹ Additional studies have suggested that traditional mapping failure might occur in up to 25% of cases after NAC, with an even higher FNR among patients with hormone-receptor positive tumors.¹⁰⁻¹²

Although the ACOSOG Z1071 trial showed decreased accuracy of SLN identification after NAC, they reported that the FNR was reduced if 3 or more nodes were retrieved, dual tracer was used, and if a radiopaque clip had been placed at the time of biopsy.^{1,13-15} Taking more than 3 lymph nodes (LNs) or using a dual tracer technique might result in removal of more unnecessary negative LNs arbitrarily and increase potential morbidity of axillary surgery. Localizing the preoperatively clipped LN with a guide wire requires additional imaging, surgical time, and potential patient discomfort. Radioactive seed localization has the additional risks associated with radiation safety and its handling/disposal.^{10,11,16-19} In this study, we describe localizing the percutaneously biopsied node (PBN) using a nonradioactive, infrared-activated fiducial reflector, the SAVI SCOUT Guidance System (SAVI SCOUT, Cianna Medical, Inc, Aliso Viejo, CA). This device is a 12-mm implantable, nonradioactive, infrared-activated, electromagnetic wave reflector. The surgeon uses a handheld probe, which produces an audible signal when immediately over the reflector.^{20,21} In our institution, we have adopted using this reflector-guided localization system to target the PBN. The primary goal of this study was to evaluate the success of identifying the PBN at the time of surgery and compare the accuracy of identifying this LN with and without reflector guidance, relative to SLNB. The secondary aim was to identify the accuracy of the PBN reflecting the status of the axilla.

Patients and Methods

Patient Population

After institutional review board approval, we prospectively identified 19 patients who underwent percutaneous ultrasound-guided needle biopsy, subsequent axillary LN reflector placement, followed by axillary SLNB. This group of 19 patients was matched for age, body mass index (BMI), clinical stage at diagnosis, histology, and receptor subtype with 19 patients who underwent conventional axillary SLNB.

Reflector Placement

Preoperatively all patients in the prospective reflector-guided group underwent preoperative ultrasonography to identify the PBN. The fiducial reflector was inserted by the breast radiologists using a single-use, sterile, preloaded 16-gauge needle (5, 7.5, or 10 cm long), using ultrasound guidance.

Surgical Intervention

All patients underwent preoperative injection with technetium-99 and intraoperative isosulfan blue dye (except for the last

4 patients who underwent reflector-guided surgery because surgeons' experience and data showed no additional benefit). Patients underwent mastectomy or breast-conserving surgery in conjunction with reflector-guided or conventional axillary SLNB. In the reflector group, the surgeon used a sterile, single-use electromagnetic probe connected to a console; when immediately placed over the reflector, an audible signal was emitted. The probe was used to rapidly identify the point of maximal intensity, which guided the surgeon directly to the marked PBN. At the time of excision, the node was characterized on the basis of tracer uptake and if the fiducial reflector was present. Mapping failure was defined as lack of tracer uptake in the PBN. Which SLN contained the fiducial reflector was noted. Specimen radiograph was obtained to confirm the presence of the fiducial reflector and/or radiopaque clip.

Retrospectively, surgical reports were reviewed for the matched cohort to identify presence or absence of a biopsy marker clip, tracer uptake, and, if a clip was present, which SLNB contained the clip or if it was present in the axillary lymph node dissection (ALND) specimen (Figure 1).

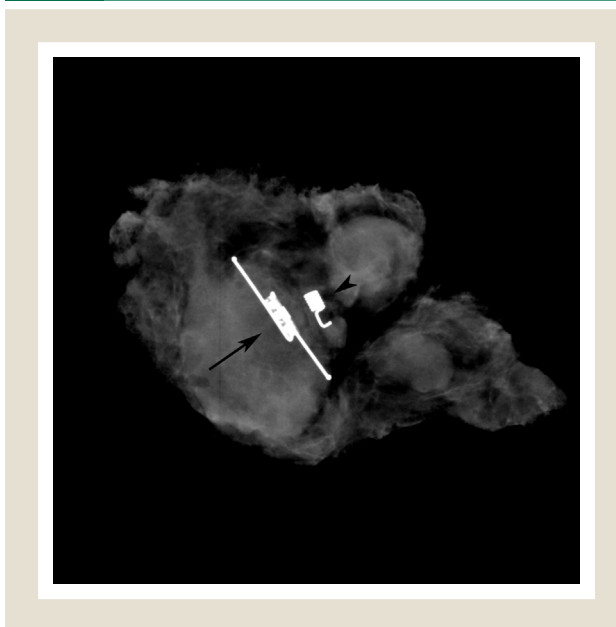
Pathologic Assessment

Final pathology was reviewed to identify the number and positivity of SLNs, total nodes positive, and pathologic response. Complete pathologic response was defined as no identifiable tumor in the breast or axilla. The "status of the axilla" was defined as positive if any LN was positive and negative if all LNs were negative.

Statistical Evaluation

Success of excising the PBN was compared in the reflector-guided and conventional groups using Fisher exact test. Statistical analysis

Figure 1 The Image Is the Specimen Radiograph, Confirming Excision of the Fiducial Reflector With the Clip, Confirming Excision of the Percutaneously Biopsied Node. The Arrowhead Marks the Clip Placed at the Time of the Percutaneous Biopsy and the Arrow the Fiducial Reflector Used to Localize the Clip



was performed using SPSS Statistics for Windows, Version 24.0 (IBM Corp, Armonk, NY). Two-tailed *P* value < .05 was defined as significant.

Results

Thirty-eight total patients were identified who underwent percutaneous axillary LN biopsy preoperatively. Of this, 19 patients (50%)

underwent reflector localized SLNB (reflector group) and 19 (50%) underwent conventional SLNB (conventional group). The median age was 48 years (range, 33-87 years) in the reflector group and 59 years (range, 32-72 years) in the conventional group. The median BMI was 28 (range, 20-44) in the reflector group and 30 (range, 22-44) in the conventional group. Among 38 patients, 16 patients (84.2%) in the reflector group and 12 patients (63.2%) in the conventional group underwent ultrasound-guided core needle biopsy. The remainder of the patients in both groups underwent fine-needle aspiration biopsy. All patients enrolled were clinically N1 at diagnosis. Tumor stage and immunohistochemistry were similar in both groups and are shown in Table 1. Six patients (31.6%) in each group showed a pathologic complete response on final pathology.

All patients underwent NAC, with 10 patients (52.6%) in the reflector group and 18 patients (94.7%) in the conventional group receiving anthracycline based treatment. Anti-HER2/*neu* therapy was administered to 3 patients (15.8%) in the reflector group and 7 patients (36.8%) in the conventional group.

At the time of percutaneous biopsy, a clip was placed in 15 patients (78.9%) in the reflector group and 13 patients (68.4%) in the conventional group. All patients in the reflector group underwent preoperative ultrasound, which identified either the clip or the PBN according to architectural landmarks. The fiducial reflector was placed percutaneously using ultrasound guidance at a mean of 2 days (range, 1-12 days) before surgery. No complications occurred in placement or retrieval of the fiducial reflector.

At the time of surgery, SLNB only was performed in 13 patients (68.4%) of the reflector group, and in 2 patients (10.5%) of the conventional group. The remainder of patients underwent SLNB followed by completion ALND.

The PBN was identified in 32 patients (84.2%). The PBN was identified by SLNB in all 19 patients (100%) in the reflector group and in only 9 patients (47.3%) in the conventional group (*P* = .0004). The PBN was identified in 4 patients (30.8%) in the ALND specimen in the conventional group. Among 6 patients without a clip, biopsy site changes were not documented and therefore it is unknown if the PBN was in the SLNB or ALND specimen. Subset analysis was performed on patients in whom the PBN was identified (reflector group, *n* = 19; conventional group, *n* = 13). Regardless of whether the PBN was identified in the SLNB or in the ALND specimen, the PBN was positive in 18 patients (56.3%) and negative in 14 patients (43.7%), correctly reflecting the status of the axilla in 100% of cases. Among the 18 patients with a positive PBN, 10 patients (56%) had additional nodes positive and in 8 patients (44.4%) this was the only LN positive for malignancy. In each case in which the PBN was the only node positive, a mean of 3.4 additional negative nodes were excised as sentinel nodes on the basis of traditional mapping techniques.

Traditional mapping techniques failed to identify the PBN similarly in both groups (36.8% of the reflector group and 46.2% of the conventional group, *P* > .01). In 7 cases in the reflector group (36.8%) the PBN was identified using reflector only. Among 32 patients, traditional mapping failed to identify the PBN in 13 patients (34.2%). The results are summarized in Table 2.

Discussion

Recently, there has been interest in decreasing the extent and morbidity of axillary surgery, particularly with the use of the SLNB

Feature	Reflector Group (n = 19)	Conventional Group (n = 19)	<i>P</i>
Median Age, Years (Range)	48 (33-81)	59 (32-72)	.1
<50	11 (57.9%)	5 (26.3%)	
>50	8 (42.1%)	14 (73.7%)	
BMI	28 (20-44)	30 (22-44)	
Type of Axillary LN Biopsy			>.1
Core needle biopsy	16 (84.2%)	12 (63.2%)	
Fine needle aspiration	3 (15.9%)	7 (36.8%)	
Clinical N Stage at Diagnosis			
N1	18 (94.7%)	16 (84.2%)	
N2	1 (5.3%)	3 (15.8%)	
Clinical T Stage at Diagnosis			>.1
T1	2 (10.5%)	1 (5.3%)	
T2	13 (68.4%)	13 (68.4%)	
T3	4 (21.1%)	4 (21.1%)	
T4	0 (0%)	1 (5.3%)	
Histology			
Ductal	18 (84.6%)	18 (94.7%)	>.1
Lobular	1 (7.7%)	1 (5.3%)	
Tumor Receptor Subtype			>.1
Hormone receptor-positive/HER2 ⁻	10 (52.6%)	6 (31.6%)	
Hormone receptor-positive/HER2 ⁺	3 (15.8%)	6 (31.6%)	
Hormone receptor-negative/HER2 ⁺	0 (0%)	1 (5.3%)	
Triple negative	6 (31.6%)	6 (31.6%)	
Neoadjuvant Chemotherapy Regimen			
Anthracycline and taxane	10 (52.6%)	18 (94.7%)	
Nonanthracycline-based	9 (42.1%)	1 (5.3%)	
Anti-HER2 Therapy			
Yes	3 (15.8%)	7 (36.8%)	
No	16 (84.2%)	12 (63.2%)	
pCR			
Yes	6 (31.6%)	6 (31.6%)	

Abbreviations: BMI = body mass index; pCR = pathologic complete response.

Reflector-Guided Sentinel Lymph Node Biopsy

Table 2 Surgical, Lymphatic Mapping, and Lymph Node Status

	Reflector Group (n = 19)	Conventional Group (n = 19)	P
Clip Placed at Time of Biopsy			
Yes	15 (78.9)	13 (68.4)	>.1
No	4 (21.1)	6 (31.6)	
Surgical Procedure			
SLNB only	13 (68.4)	2 (10.5)	.0006
SLNB with completion ALND	6 (31.6)	17 (89.5)	
Sentinel Lymph Node			
Identified successfully	19 (100)	17 (89.5)	>.1
Median identified (range), n	2 (1-5)	3 (1-5)	
Median pathology (range), n	4 (2-10)	4 (1-7)	
PBN			
Identified at SLNB	19 (100)	9 (47.5)	.0004
Identified at ALND	0 (0)	4 (30.8)	.03
Not identified	0 (0)	6 (31.6)	.02
Mapped with traditional agents	12 (63.2)	7 (53.8)	>.1
Traditional mapping failure	7 (36.8)	6 (46.2)	>.1
Accurately predicted axillary status	19 (100)	13 (100)	>.1
PBN-positive	10 (52.6)	8 (61.5)	
Only positive node	4 (40)	4 (50)	
PBN-negative	9 (47.4)	5 (38.5)	
Identified using reflector only	7 (36.8)	—	
Clipped Nodes, n	15	13	
Clip identified in ALND specimen	0 (0)	4 (30.8)	.03
Clipped node positive	10 (66.6)	7 (53.8)	>.1
Only lymph node positive	4 (26.7)	3 (23.1)	
Mean, Total Nodes Excised, n	8.1	15.4	
Mean, Total Nodes Positive, n	1.5	1.4	
Patients With Residual Nodal Disease	10 (52.6)	9 (47.5)	
Positive non-SLN only	0 (0)	3 (33.3)	
FNR, %	0	33.3	.2

Data are presented as n (%) except where otherwise noted. Abbreviations: ALND = axillary lymph node dissection; FNR = false negative rate; PBN = percutaneously biopsied node; SLNB = sentinel lymph node biopsy.

technique. However, its accuracy after NAC remains limited, particularly in cases in which fewer than 3 SLNs were removed, using a single agent for lymphatic mapping, and hormone receptor-positive tumor types. Although the ACOSOG Z1071 trial identified methods to decrease the FNR, each of these techniques is not

without risk.^{1,13,15} Testing 3 or more nodes might be unnecessary, resulting in excising excessive negative nodes, and increasing surgical morbidity including the risk for lymphedema. Dual tracer techniques might fail in up to 25% of patients who undergo NAC and do not discriminate the biopsied node from another LN.^{10,11} Blue dye has been associated with allergic reactions and rarely anaphylaxis.²²⁻²⁴ Furthermore, studies discussing SLNB after NAC report success in finding a sentinel node, not necessarily the PBN. The PBN, especially when positive, might show treatment response, which was also not clearly reported in all studies assessing SLNB after NAC.^{1,8,9} Finally, attempting to identify a clipped node without localization might result in excision of additional arbitrary LNs, increased surgical time, and requires multiple specimen radiographs.

To overcome the limitations of traditional SLNB, localization of the clipped node has been described using wire guidance or radioactive seed all with associated risks and inconveniences.^{10,11,16-19,25} Wire localization requires same-day placement, risk for dislodgement, and patient discomfort. Radioactive seed placement, although decouples operating room with radiology scheduling, poses patient and physician exposure as well as institutional safety concerns.^{10,11,16,17,19} Although technology, like the MagSeed (Endomagetics, Inc, Austin, TX), have been considered, magnetic seed localization also requires a separate probe, is similarly priced, and requires nonmetal retractors. The reflector-guided system described in this report avoids a wire in the axilla and the deploying needle is similar in size to a typical percutaneous biopsy device.

Herein we describe the technique of using a nonradioactive, infrared-activated fiducial reflector, placed before the day of surgery, to guide conventional SLNB technique for more accurate identification of the PBN. The reflector-guided system described herein avoids patient and institutional safety concerns, as well as radioactive seed handling precautions. In contrast to wire localization, the reflector overcomes same-day placement, potential dislodgement, and patient discomfort. This reflector-guided technique allows facile and rapid identification of the PBN, without the limitations of other localization methods.

Without localization, identifying the PBN depends on traditional mapping techniques for SLNB: technetium-99 and blue dye (lymphazurin, or methylene blue).¹² Radioisotope injection is often performed in the Nuclear Medicine Department, which is associated with additional labor and costs, and when used alone after NAC has been associated with an increase in FNR. Blue dye mapping has been associated with anaphylaxis (lymphazurin) and skin necrosis (methylene blue) and might not map to the axilla in cases it is injected in the operating room.²⁶ The patients in the reflector group underwent conventional mapping in addition to reflector targeting. Although the SLN identification rate in both groups was similar to published rates, identifying the PBN was significantly higher in the reflector group (100% vs. 47.3%; $P = .002$; Table 2).

In this study we identified a 34% mapping failure to the PBN using the conventional mapping techniques, which is similar to rates after NAC reported in the literature.^{10,11,15} Moreover, mapping failure has been shown to be more common among patients who undergo NAC for hormone receptor-positive cancer, in whom response might be less frequent and conventional mapping might lead to a false negative node.¹² Fiducial reflector guidance allows for

directed placement by the radiologist, regardless of previous clip placement. In the few patients without clip placement, adjacent landmarks can be identified by the radiologist (ie, proximity to the pectoralis muscle, nearby vasculature, depth of initial biopsy) are easily identified by comparing real-time sonography to imaging before NAC. Although we found an increase in mapping failure among patients with hormone receptor-positive cancers, power was insufficient to establish a clear correlation. Without excising the PBN, we risk incomplete surgery in those with residual disease or excessive dissection in patients with a pathologic complete response. Therefore, reflector-guided excision of the PBN is the most facile and consistent method to reflect the status of the axilla and overcomes the limitations of traditional mapping techniques. The PBN was identified in 100% of patients who underwent reflector guidance, and the histopathology of the PBN reflected the status of the axilla. When the PBN was negative, there were no cases of other positive LNs.

Identifying the status of the axillary LNs after chemotherapy is paramount to assessing treatment response, and prognosis.^{1,13-15} As the use of NAC becomes more popular, methods to more accurately assess the axillary response are needed. Ideally, an approach that is minimally invasive, least intrusive to the patient, cost-effective, facile, and removes the least number of LNs with the greatest accuracy is needed. This study shows the clinical utility of using an infrared-activated fiducial reflector placed before surgery to guide SLNB of the PBN. This technique improved the accuracy of SLNB and its reflection of the axillary LN status after NAC. In our experience, this approach was well tolerated and convenient for the patient as well as for the operating surgeon and allowed for more rapid and precise identification of the PBN. In addition, there was a trend toward the identification of fewer SLNs when the PBN was marked with a fiducial reflector.

This study was established to explore the feasibility and success of identifying a PBN using reflector guidance. Our findings demonstrate a novel approach that might overcome the need for dual tracer use and the need for resecting additional SLNs as suggested by ACOSOG Z1071 as well as the SENTinal NeoAdjuvant (SENTINA) trials to ensure a lower FNR in patients who undergo NAC.^{1,2} When the reflector-guided method described herein is used, it not only overcomes the inconveniences of other localization methods, but also identifies the PBN as the sentinel node in 100% of cases, compared with 47.3% using conventional sentinel node techniques alone. Therefore, identifying and excising the PBN provides the most reliable method of determining if the remainder of the axilla has responded to chemotherapy.

Conclusion

Sentinel LN biopsy with traditional mapping agents after NAC might result in mapping failure and unintentional excision of additional LNs. Reflector-guided PBN resection dramatically improves SLNB after NAC, more precisely reflecting the status of the axilla, and allows removal of fewer LNs. These findings provide the first evidence that PBN excision might optimize and minimize axillary surgery in patients who undergo NAC for node-positive disease.

Clinical Practice Points

- Sentinel lymph node biopsy after NAC has an FNR of approximately 12%. Identifying the PBN, or clipped node, can decrease the FNR.
- To date, the techniques discussed in the literature to target dissection to the clipped node involve placing wires or radioactive seeds in the axilla, both of which have institutional coordination and safety concerns, respectively.
- This new technique involves a reflector placed in the axilla which is nonradioactive and uses a separate hand piece, which is less cumbersome and more efficient.
- Because the PBN predicts the status of the remaining lymph nodes in the axilla, this is the best tool to identify treatment response in the axilla.

Disclosure

The authors have stated that they have no conflicts of interest.

Supplemental Data

The supplemental data accompanying this article can be found in the online version at <https://doi.org/10.1016/j.clbc.2018.02.001>.

References

1. Boughey JC, Suman VJ, Mittendorf EA, et al. Sentinel lymph node surgery after neoadjuvant chemotherapy in patients with node-positive breast cancer: the ACOSOG Z1071 (Alliance) clinical trial. *JAMA* 2013; 310:1455-61.
2. Kuehn T, Bauerfeind I, Fehm T, et al. Sentinel-lymph-node biopsy in patients with breast cancer before and after neoadjuvant chemotherapy (SENTINA): a prospective, multicentre cohort study. *Lancet Oncol* 2013; 14:609-18.
3. Krag D, Harlow S, Julian T. Breast cancer and the NSABP-B32 sentinel node trial. *Breast Cancer* 2004; 11:221-4 [discussion: 264-266].
4. Kim T, Giuliano AE, Lyman GH. Lymphatic mapping and sentinel lymph node biopsy in early-stage breast carcinoma: a metaanalysis. *Cancer* 2006; 106:4-16.
5. Veronesi U, Paganelli G, Viale G, et al. Sentinel-lymph-node biopsy as a staging procedure in breast cancer: update of a randomised controlled study. *Lancet Oncol* 2006; 7:983-90.
6. Krag DN, Anderson SJ, Julian TB, et al. Technical outcomes of sentinel-lymph-node resection and conventional axillary-lymph-node dissection in patients with clinically node-negative breast cancer: results from the NSABP B-32 randomised phase III trial. *Lancet Oncol* 2007; 8:881-8.
7. Xing Y, Cormier JN, Kuerer HM, Hunt KK. Sentinel lymph node biopsy following neoadjuvant chemotherapy: review of the literature and recommendations for use in patient management. *Asian J Surg* 2004; 27:262-7.
8. Fu JF, Chen HL, Yang J, Yi CH, Zheng S. Feasibility and accuracy of sentinel lymph node biopsy in clinically node-positive breast cancer after neoadjuvant chemotherapy: a meta-analysis. *PLoS One* 2014; 9:e105316.
9. Mamounas EP, Brown A, Anderson S, et al. Sentinel node biopsy after neoadjuvant chemotherapy in breast cancer: results from National Surgical Adjuvant Breast and Bowel Project Protocol B-27. *J Clin Oncol* 2005; 23:2694-702.
10. Caudle AS, Yang WT, Krishnamurthy S, et al. Improved axillary evaluation following neoadjuvant therapy for patients with node-positive breast cancer using selective evaluation of clipped nodes: implementation of targeted axillary dissection. *J Clin Oncol* 2016; 34:1072-8.
11. Diego EJ, McAuliffe PF, Soran A, et al. Axillary staging after neoadjuvant chemotherapy for breast cancer: a pilot study combining sentinel lymph node biopsy with radioactive seed localization of pre-treatment positive axillary lymph nodes. *Ann Surg Oncol* 2016; 23:1549-53.
12. Enokido K, Watanabe C, Nakamura S, et al. Sentinel lymph node biopsy after neoadjuvant chemotherapy in patients with an initial diagnosis of cytology-proven lymph node-positive breast cancer. *Clin Breast Cancer* 2016; 16:299-304.
13. Boughey JC, Ballman KV, Le-Petross HT, et al. Identification and resection of clipped node decreases the false-negative rate of sentinel lymph node surgery in patients presenting with node-positive breast cancer (T0-T4, N1-N2) who receive neoadjuvant chemotherapy: results from ACOSOG Z1071 (Alliance). *Ann Surg* 2016; 263:802-7.
14. Boughey JC, McCall LM, Ballman KV, et al. Tumor biology correlates with rates of breast-conserving surgery and pathologic complete response after neoadjuvant chemotherapy for breast cancer: findings from the ACOSOG Z1071 (Alliance) prospective multicenter clinical trial. *Ann Surg* 2014; 260:608-14 [discussion: 614-616].

Reflector-Guided Sentinel Lymph Node Biopsy

15. Boughey JC, Suman VJ, Mittendorf EA, et al. Factors affecting sentinel lymph node identification rate after neoadjuvant chemotherapy for breast cancer patients enrolled in ACOSOG Z1071 (Alliance). *Ann Surg* 2015; 261:547-52.
16. Donker M, Straver ME, Wesseling J, et al. Marking axillary lymph nodes with radioactive iodine seeds for axillary staging after neoadjuvant systemic treatment in breast cancer patients: the MARI procedure. *Ann Surg* 2015; 261:378-82.
17. Koolen BB, Donker M, Straver ME, et al. Combined PET-CT and axillary lymph node marking with radioactive iodine seeds (MARI procedure) for tailored axillary treatment in node-positive breast cancer after neoadjuvant therapy. *Br J Surg* 2017; 104:1188-96.
18. Plecha D, Bai S, Patterson H, Thompson C, Shenk R. Improving the accuracy of axillary lymph node surgery in breast cancer with ultrasound-guided wire localization of biopsy proven metastatic lymph nodes. *Ann Surg Oncol* 2015; 22:4241-6.
19. Straver ME, Loo CE, Alderliesten T, Rutgers EJ, Vrancken Peeters MT. Marking the axilla with radioactive iodine seeds (MARI procedure) may reduce the need for axillary dissection after neoadjuvant chemotherapy for breast cancer. *Br J Surg* 2010; 97:1226-31.
20. Mango V, Ha R, Gomberwalla A, Wynn R, Feldman S. Evaluation of the SAVI SCOUT surgical guidance system for localization and excision of nonpalpable breast lesions: a feasibility study. *AJR Am J Roentgenol* 2016;W1-4. [Epub ahead of print].
21. Mango VL, Wynn RT, Feldman S, et al. Beyond wires and seeds: reflector-guided breast lesion localization and excision. *Radiology* 2017; 284:365-71.
22. Albo D, Wayne JD, Hunt KK, et al. Anaphylactic reactions to isosulfan blue dye during sentinel lymph node biopsy for breast cancer. *Am J Surg* 2001; 182:393-8.
23. Cimmino VM, Brown AC, Szocik JF, et al. Allergic reactions to isosulfan blue during sentinel node biopsy—a common event. *Surgery* 2001; 130:439-42.
24. Montgomery LL, Thorne AC, Van Zee KJ, et al. Isosulfan blue dye reactions during sentinel lymph node mapping for breast cancer. *Anesth Analg* 2002; 95: 385-8, table of contents.
25. van Nijnatten TJ, Simons JM, Smidt ML, et al. A novel less-invasive approach for axillary staging after neoadjuvant chemotherapy in patients with axillary node-positive breast cancer by combining radioactive iodine seed localization in the axilla with the sentinel node procedure (RISAS): a Dutch prospective multicenter validation study. *Clin Breast Cancer* 2017; 17:399-402.
26. Rauch P, Merlin JL, Leufflen L, et al. Limited effectiveness of patent blue dye in addition to isotope scanning for identification of sentinel lymph nodes: cross-sectional real-life study in 1024 breast cancer patients. *Int J Surg* 2016; 33:177-81.