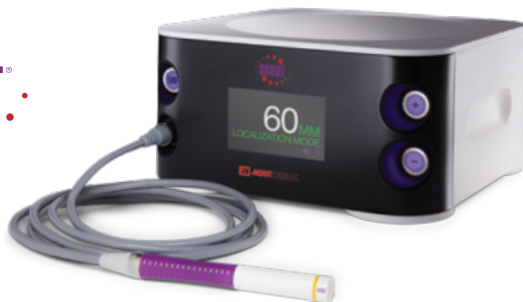



Long-Term Reflector Placement

Gail Starr, MD, MEd

Hackensack University Medical Center
Hackensack, NJ

Patient: 73-year-old female

Diagnosis: Atypical ductal hyperplasia

Procedure: Localization of multiple sites in the left breast

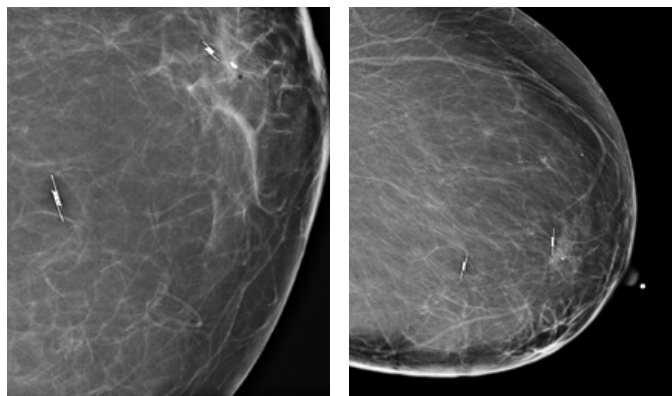
Challenge: SCOUT® localized surgery delayed due to cardiac clearance

Patient History

The patient is a 76 year old female who had indeterminate calcifications identified on a screening mammogram which warranted biopsy. She has a personal history of lung cancer s/p chemotherapy and XRT asthma/COPD and HTN.

She had a screening mammogram followed by additional views in March 2016. A stereotactic core biopsy was subsequently performed yielding ADH. Localization and excision was recommended but not performed.

The patient returned in September 2016 and had a unilateral follow up mammogram. In view of the atypia it was determined that in addition to excision of the biopsied lesion, another faint group should be localized as well.



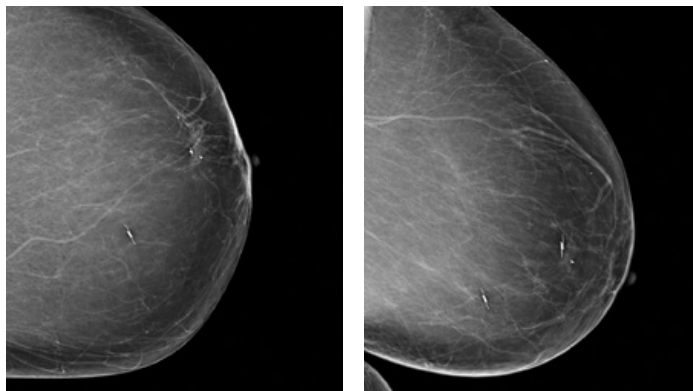
10/2016 Post-placement mammography images

Localization

In preparation for surgery, the patient had two SCOUT reflectors placed in October 2016. One reflector was placed in the retroareolar region at the site of the STCB yielding ADH with residual calcifications and a top hat shaped clip. The second reflector was placed to sample faint calcifications in the LIQ. Post-localization radiographs confirmed positioning.

In the days following the localization procedure, the anesthesiologist cancelled surgery, requiring cardiac clearance. Her course was complicated by COPD/Chronic lung disease with episodes of shortness of breath resulting in visits to the ER.

She returned in February 2017 for mammographic imaging, which demonstrated that the reflectors remained accurately positioned. She was still not cleared by her cardiologist, as a cardiac catheterization was recommended.



5/2017 Pre-surgery mammography images

Surgery

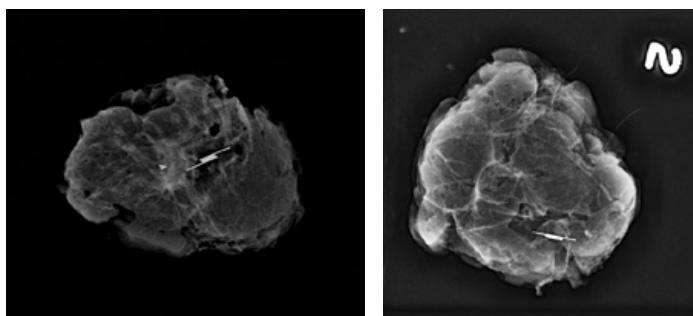
In May 2017, she returned to radiology for imaging, where it was confirmed that the reflectors had not moved and could be detected in both supine and erect positions. The following week, over 6 months since placement of the reflectors, the specimen was successfully retrieved. Two specimen X-rays, each submitted with a reflector and calcifications, demonstrated successful localization.

Pathology

Final path: Hyalinized FA and fibroadenomatoid change.

Conclusion

The SCOUT reflectors did not move within the breast, created no untoward symptoms for the patient, and were easily detected more than 6 months after placement, allowing for long term placement.



5/2017 Specimen X-rays



ciannamedical.com/savi-scout
merit.com

The foregoing case and other information are for the practitioner's convenience and for general information purposes only. This information does not constitute medical or legal advice, nor is it meant to endorse or guarantee the suitability of any of the referenced products or methods for any specific patient or procedure. Before using any product, refer to the Instructions for Use (IFU) for indications, contraindications, warnings, precautions, and directions for use.