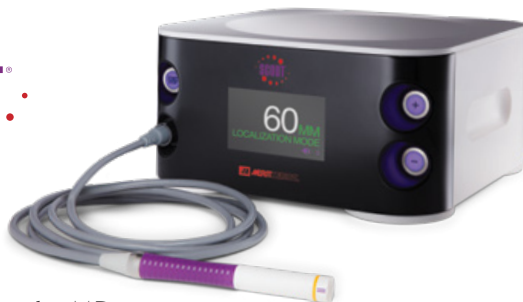



Single Axillary Incision for both Sentinel Lymph Node Biopsy and Lumpectomy

Allison DiPasquale, MD

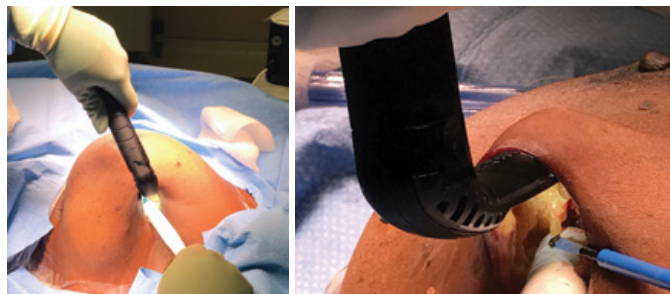
Breast Surgical Oncologist
Texas Oncology, Dallas, TX

Patient: 54-year-old female

Dx: Invasive Ductal Carcinoma, Stage II (T2 N0 M0)

Rx: Left SCOUT® localized lumpectomy with sentinel lymph node biopsy

Challenge: Single axillary incision for both sentinel lymph node biopsy and lumpectomy



Figures 2 and 3: SCOUT handpiece used through axillary incision to guide dissection.

Patient History

The patient is a 54-year-old female who underwent screening mammogram that showed left calcifications and upon further diagnostic imaging, including an MRI, there appeared to be a 2.7 cm left breast mass in the 11 o'clock position. Biopsy was performed and revealed invasive ductal carcinoma ER positive, PR positive, HER-2/neu negative with a Ki-67 of 10%. Since the patient was young, had a sizable tumor and wished to obtain genetic testing prior to deciding on surgical management, neoadjuvant chemotherapy was instituted with AC followed by T.

Her postchemotherapy imaging showed that the mass had decreased in size to 0.9 cm in largest dimension concentrically. Her genetic testing showed a variant of uncertain significance in the PTEN gene. Thus, she wished to pursue breast conservation.

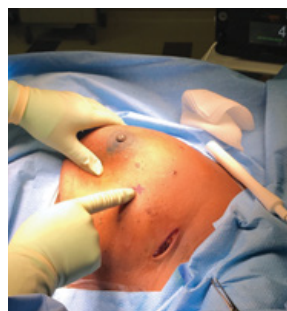


Figure 1: Lesion location relative to axillary incision.

Surgery

Since the tumor was located in the upper outer quadrant and the patient was concerned with cosmesis, a single incision was used to perform both the breast and axillary surgery. The tumor was located approximately 5.5 cm from the axilla on intraoperative SCOUT® evaluation.

In the left axilla a 3 cm incision was made just anterior to the hairbearing line where there

was the highest level of radioactivity found by the gamma probe. The first step of the procedure included a sentinel lymph node biopsy where there was found to be two hot and blue sentinel lymph nodes. Once the portion of the lymph node surgery was completed the clavipectoral fascia was closed in entirety using

a running 3-0 Vicryl suture to exclude this from a breast tunnel. Once closed, a tunnel was raised using the SCOUT system as well as lighted retractors for guidance towards the cancer. The SCOUT system was then utilized to create the inferior and medial margins around the tumor, followed by the lateral margin. The tissue was then pulled posteriorly in order to dissect free the lumpectomy specimen by making the superior margin. Shaved margins were acquired in the anterior, posterior, superior, inferior, medial, and lateral positions and marked with a stitch on true margin. Next, tissue advancement flaps were incised and mobilized to allow for closure of the defect in the tunnel. Prior to closing the defect, a bioabsorbable marker was implanted into the lumpectomy cavity and sutured into place. The tissue advancement flaps were closed over the top of the marker until the defect was completely obliterated. The wound was closed in layers covered with Dermabond.

Pathology

Pathology revealed a 0.8 cm residual tumor with surrounding DCIS and negative margins with negative lymph nodes.

Postoperative Course

The patient recovered remarkably well with no signs of infection, seroma or hematoma. The single axillary incision allowed for beautiful contour of the breast with no incisions on the breast.

Conclusion

The utilization of SCOUT® allows the surgeon to choose the ideal incision location. In this case, a single axillary incision was utilized for both the lymph node and breast cancer for a beautiful aesthetic outcome.

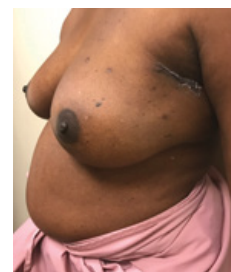

Figure 4: 2 weeks post-op



ciannamedical.com/savi-scout
merit.com

The foregoing case and other information are for the practitioner's convenience and for general information purposes only. This information does not constitute medical or legal advice, nor is it meant to endorse or guarantee the suitability of any of the referenced products or methods for any specific patient or procedure. Before using any product, refer to the Instructions for Use (IFU) for indications, contraindications, warnings, precautions, and directions for use.