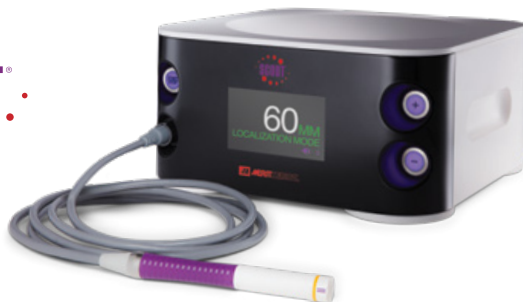



# Skin Sparing Mastectomy with SCOUT®

## Erica Giblin, MD

Breast Surgical Oncologist  
Medical Director, Breast Care Services  
St. Vincent Medical Group, Indianapolis, IN

**Patient:** 45-year-old female

**Diagnosis:** Invasive Ductal Carcinoma, Multiple Locations  
Right Breast, Stage II (T2 N0 M0)

**Rx:** SCOUT localized bilateral skin sparing mastectomy with sentinel lymph node biopsy

**Challenge:** Obtaining Adequate Anterior Margins with Superficial Lesions

### Patient History

The patient is a 45-year-old female who presented with a right palpable mass in the 12:00 position, identified on self-examination. She underwent bilateral diagnostic mammogram which demonstrated extremely dense breast tissue and no abnormal findings. Right breast US of the 12:00 location 3 CFN revealed a 2.2 cm irregular mass (Figure 1) and right breast US of the 10:00 location, 1 CFN revealed a 0.6 cm nodule with irregular

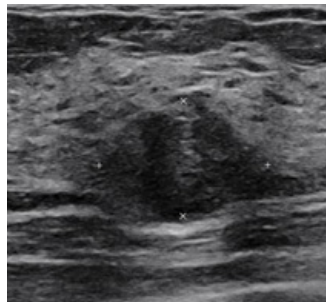


Figure 1

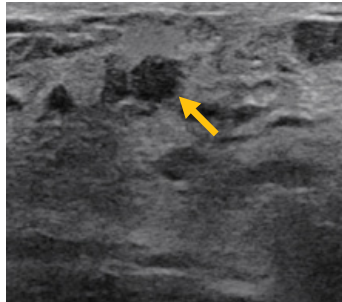


Figure 2

margins (Figure 2). US of the right axilla revealed normal appearing nodes. Core biopsy of the 12:00 lesion revealed grade II invasive ductal cancer with mucinous features, ER 77%, PR 0%, and Her 2 equivocal (FISH negative). Pathology of the right 10:00 lesion revealed grade II invasive ductal cancer, ER 84%, PR 0%, and Her2 equivocal (FISH negative). Family history is notable with four maternal uncles with prostate cancer and maternal grandfather with pancreatic cancer. Patient underwent panel genetic testing which revealed that she carries the PALB2 mutation.

Given her extreme breast density on mammography breast MRI was recommended, which demonstrated enhancing masses at the location of biopsy markers. The 10:00 position mass measured approximately 1 cm, and the 12:00 position mass measured approximately 2.2 x 2 x 2.1 cm. A third mass identified was highly suspicious for malignancy and was located cephalad to the 12:00 and measured approximately 1.5 x 0.8 x 0.8 cm. No evidence of involvement of the skin. No definite abnormal axillary or internal mammary lymph nodes identified.

### Surgery

Patient desired bilateral skin sparing mastectomy with direct to implant reconstruction. Based on the imaging findings of the superficial nature of the right 10:00 and 12:00 lesions, two SCOUT reflectors were placed prior to surgery to provide intraoperative identification of these lesions. The 1:00 lesion was located deeper in the breast parenchyma and therefore did not undergo SCOUT localization. Such an approach facilitates modification of mastectomy flap thickness in the focal area of concern that is localized with SCOUT to assist in obtaining adequate anterior margin.

### Pathology

Pathology of the right breast revealed 3 separate foci of invasive ductal cancer with the 12:00 area demonstrating 3.2 cm of invasive ductal carcinoma with mucinous features, the 10:00 area demonstrating 1.2 cm of invasive ductal carcinoma, and a 1.5 cm invasive ductal cancer 2 cm medial to the 12:00 lesion. Three sentinel nodes were obtained and were negative for metastatic carcinoma.

### Conclusion

This case illustrates the utility of SCOUT localization for patients who are undergoing mastectomy, particularly for superficial lesions. The ability to localize the superficial area(s) of concern allows the surgeon to adjust the mastectomy flap thickness to help obtain a negative anterior margin.

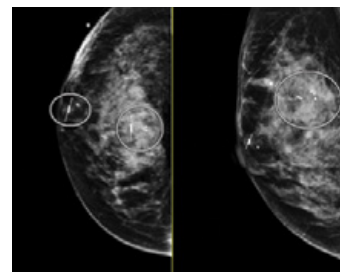


Figure 3: Post-localization mammogram showing SCOUT reflector placements

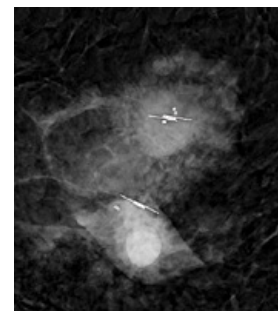


Figure 4: Right mastectomy specimen containing both core biopsy clips and adjacent SCOUT reflectors



[ciannamedical.com/savi-scout](http://ciannamedical.com/savi-scout)  
[merit.com](http://merit.com)

The foregoing case and other information are for the practitioner's convenience and for general information purposes only. This information does not constitute medical or legal advice, nor is it meant to endorse or guarantee the suitability of any of the referenced products or methods for any specific patient or procedure. Before using any product, refer to the Instructions for Use (IFU) for indications, contraindications, warnings, precautions, and directions for use.