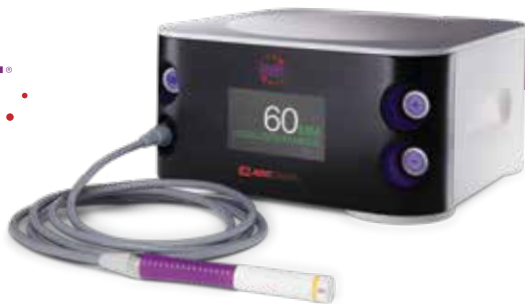



Interpectoral Breast Cancer Recurrence Localized with SCOUT® Radar Localization

Dr. Chantel Thornton BMSc (hons) MBBS (hons) FRACS

General Surgery & Gastroenterology Clinical Institute
Epworth Hospital, Victoria, Australia.

Patient History

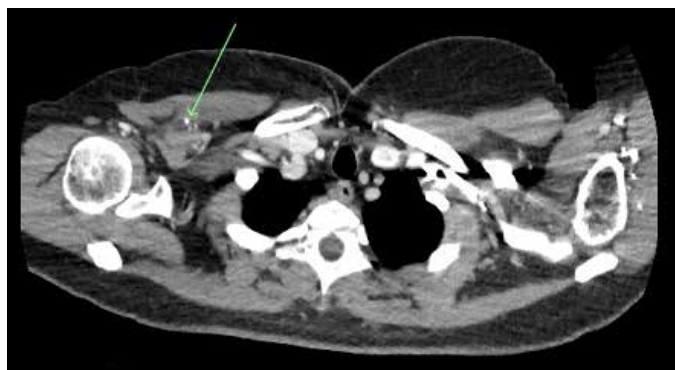
A 48-year-old woman had earlier presented with multi-focal cancer of the right breast. Patient underwent a right skin-sparing mastectomy the excision of the nipple and areolar complex and a right axillary lymph node dissection with an immediate DIEP flap reconstruction.

Patient Work-Up

Four years after her original cancer diagnosis she presented with a hypoechoic nodule 3 cm inferior to the right clavicle 4 x 6 mm deep to the pectoralis muscle. This was noted during annual ultrasound surveillance.

An MRI at that stage of the reconstructed breast did not show any abnormality. Ultrasound-guided fine needle aspiration was undertaken of the infraclavicular nodule and revealed cytological changes consistent with recurrent micropapillary cancer. The patient proceeded to a core biopsy and a clip was placed. Biopsy confirmed micropapillary carcinoma from the breast [ER+ PR- HER2+]

A CT scan of the chest, abdomen and pelvis revealed no other metastatic disease except for a nodule with a clip 1 cm deep to the right pectoralis minor in the infraclavicular position with no other lymphadenopathy (Fig. 1). An MRI of the brachial plexus revealed enhancement in the intramuscular plane between the right pectoralis minor and major at the level of the clavicle, consistent with disease recurrence. A pet scan revealed no concerning features.

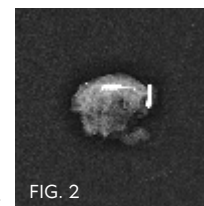


Localization & Surgery

The patient was localized with a SCOUT Reflector on the same day-of-surgery.

An anterior approach was undertaken and an incision inferior to the clavicle and the pectoralis fascia was opened with diathermy. The pectoralis major and minor muscles were separated split using blunt dissection and a self-retainer.

The SCOUT Surgical Guide was successfully used to identify the SCOUT Reflector that had been previously implanted in the nodule. The Reflector was detected throughout dissection, and a clip was placed on a small vessel before excision of the soft tissue nodule. The presence of the SCOUT Reflector was confirmed using the Guide in the excised specimen, and the Reflector was visualized on Specimen Radiograph (Fig. 2).



The patient was reviewed 48-hours post operation and reported minimal pain. The position of the recurrence would have made it technically impossible to perform the operation with a hookwire; the wire would have been dislodged soon after the muscle had been dissected.

Final histopathology revealed soft tissue with an eight-millimeter soft tissue deposit of poorly differentiated micro papillary carcinoma from the breast. Clear of the planes of resection, there was a single small benign lymph node in the adjacent soft tissue. The cancer was ER+ PR- HER2+.

The patient will now be treated with pertuzamab and radiotherapy. The recurrence was just lateral to her prior supra clavicular radiotherapy field, and it appears that this soft tissue nodule was outside the original radiotherapy treatment field.

Conclusion & Remarks

The SCOUT Reflector was easily implanted and repeatedly detected throughout surgery. The multiple dissection options provided by the Reflector, and the repeated and immediate detection feedback, proved valuable given the difficult anatomical location of this recurrence.

These suggestions and other information, which may include both Merit and third-party products, are for the practitioner's convenience and for general information purposes only. This information does not constitute medical or legal advice, nor is it meant to endorse or guarantee the suitability of any of the referenced products or methods for any specific patient or procedure. Before using any product, refer to the Instructions for Use (IFU) for indications, contraindications, warnings, precautions, and directions for use.



Understand. Innovate. Deliver.™

merit.com
merit.com/merit-oncology

Merit Medical Systems, Inc.
1600 West Merit Parkway
South Jordan, Utah 84095
1.801.253.1600
1.800.35.MERIT

Merit Medical Australia
53 Canterbury Road
Braeside VIC
Australia
+61 1300 696 374

Merit Medical New Zealand
4/4 Rawiri Place
Hobsonville, Auckland
New Zealand
+64 9 964 0591