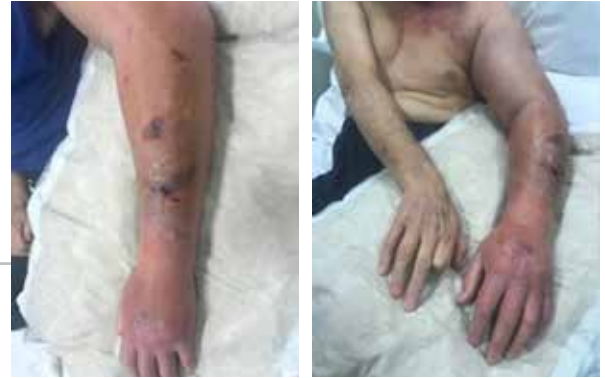



## Treatment of a recurrent left subclavian vein occlusion with WRAPSODY™



**Dr Dean Huang**  
Interventional Radiologist  
King's College Hospital, London, UK



### CLINICAL HISTORY

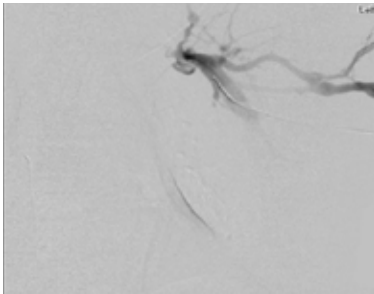
A 56-year-old male patient on haemodialysis for 5 years with an history of eight previous venoplasty procedures to treat recurrent left subclavian vein stenosis, presented with a severe arm, face, and neck swelling, as shown in the image to the right.

### INTERVENTIONAL TREATMENT

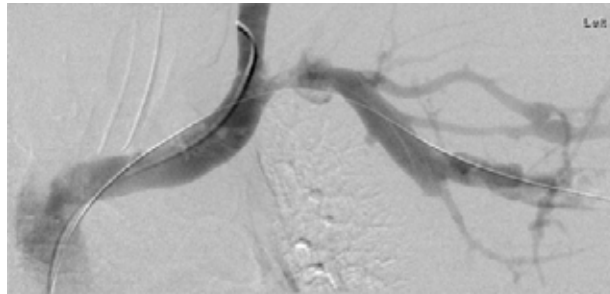
Left subclavian occlusion was initially crossed from left fistula access via a 5 Fr sheath (BRITE TIP, Cordis). Right groin common femoral vein access was then obtained and a 14 Fr sheath positioned.

A through and through wire (0'035 STORQ, Cordis) from the right common femoral vein sheath and the left upper arm sheath was established.

The left subclavian vein stenosis was initially dilated with serial balloons 6mm, 10 mm, 14 mm.

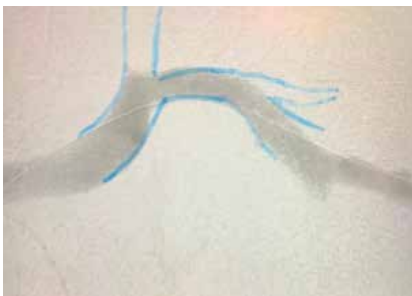

Pre-venoplasty

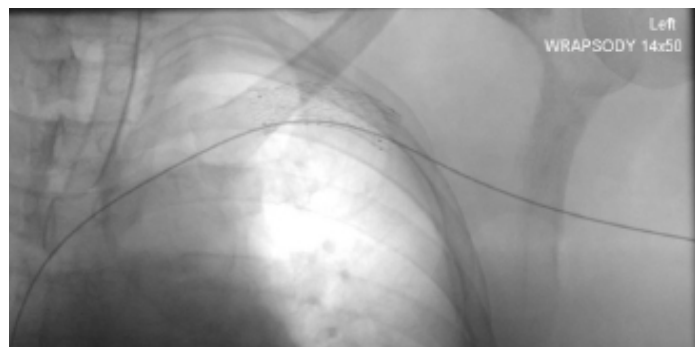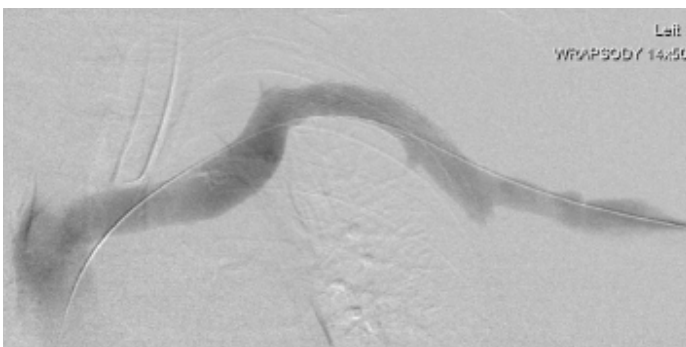


Post-venoplasty

Venogram mapping out left internal jugular vein/left subclavian vein confluence was performed.



Then, A **WRAPSODY Cell-impermeable Endoprosthesis (14mm x 50 mm)** was deployed across the left subclavian vein stenosis, immediately beyond the origin of the left internal jugular vein precisely without covering the left subclavian vein insertion.

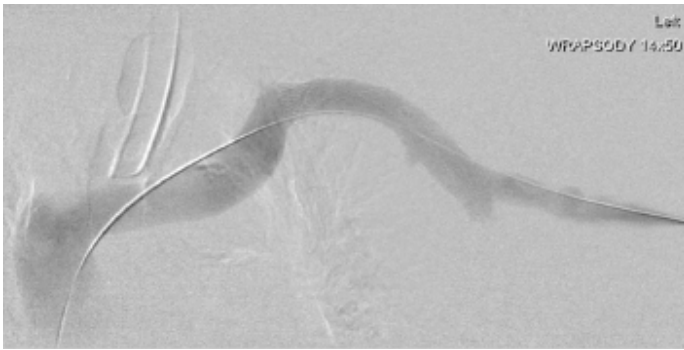


Post Wrapsody implantation

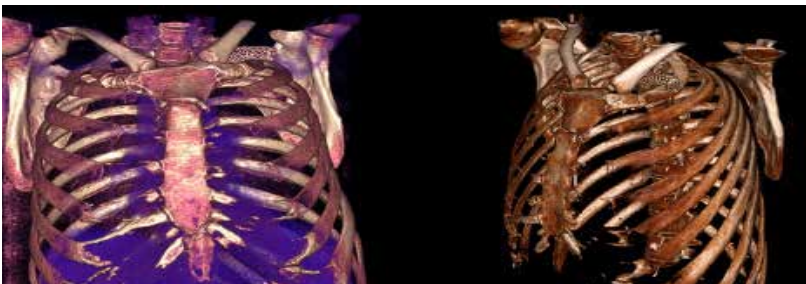
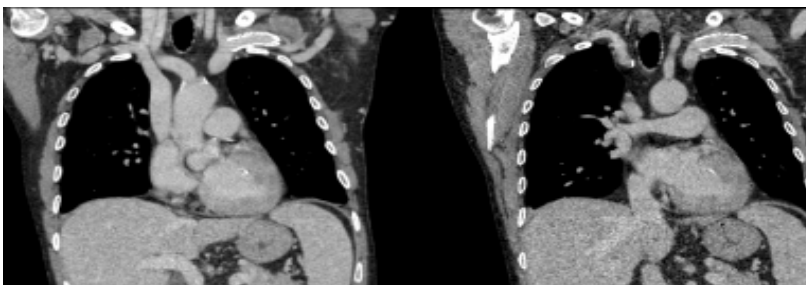
Inflation of a 14 mm balloon within WRAPSODY was performed following implantation.

## CLINICAL RESULTS

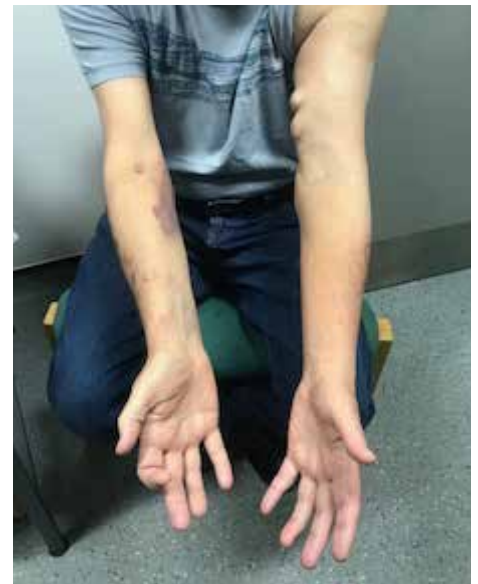The final venogram showed good angiographic result with no complication.



The sheaths were removed, and haemostasis was achieved with purse string suture at fistula puncture site and compression to groin puncture site. A CT scan was performed 7 days post-implantation, which showed a patent and well positioned WRAPSODY, minimal distal angulation to the course of the vein without significant stenosis.



CT follow-up



The photo was taken 13 days apart

Duplex ultrasound was performed at the puncture sites which reveals no pseudoaneurysm or a significant haematoma.

According to patient the arm swelling went down by 70-80% by day 4 post op and by the time the post photo was taken, patient felt it was pretty much as normal as the other arm. Patient was extremely pleased and grateful for the outcome.

It is really satisfying to see WRAPSODY making **such a big impact for the patient.**

## KEY TAKEAWAYS

**Precise positioning of the WRAPSODY** is required to ensure the patency of the left internal jugular vein is maintained. In this case, even with the right femoral vein approach to reach the left subclavian vein stenosis, the WRAPSODY deployment accuracy was easily achieved.

This product is intended for sale and/or use only in the European Union, for use in hemodialysis patients for the treatment of stenosis or occlusion within the dialysis outflow circuit of an arteriovenous (AV) fistula or AV graft. This product is not approved, cleared or available for sale or use in the United States, and may not be approved, cleared or available for sale or use in other countries. Before using any product, refer to the Instructions for Use (IFU) for indications, contraindications, warnings, precautions, and directions for use.



Understand. Innovate. Deliver.™

merit.com  
merit.com/wrapsody

©2022 Merit Medical Systems, Inc. All rights reserved.

Merit Medical Systems, Inc.  
1600 West Merit Parkway  
South Jordan, Utah 84095  
1.801.253.1600  
1.800.35.MERIT

Merit Medical Europe, Middle  
East & Africa (EMEA)  
Amerikalaan 42, 6199 AE  
Maastricht-Airport  
The Netherlands  
+31 43 358 82 22

Merit Medical Australia  
53 Canterbury Road  
Braeside VIC  
Australia  
+61 1300 696 374

Merit Medical New Zealand  
4/4 Rawiri Place  
Hobsonville, Auckland  
New Zealand  
+64 9 964 0591

407351101\_001 ID 042522